

# Internal Hemipelvectomy in Pelvic Girdle Tumors A Limb Saving Procedure

Amr Attia, MD  
NCI, Cairo University

# Introduction

**The annual incidence of malignant neoplasms of bone is less than 1 in 100,000. about 5% of malignant tumors in persons < 20 years.**

**Poor prognosis & amputative surgery made the treatment difficult in the past.**

**Resection of these tumors leaving a functioning limb was the target of considerable effort.**

# Introduction

The success of these limb salvage techniques has been due to:

- ❖ The developing of intensive neoadjuvant chemotherapy & radiotherapy.
- ❖ Improvement of skeletal reconstruction techniques.

# Patients & Methods

**34 patients (NCI, 1993-2003) were selected for internal hemipelvectomy. Resections. Of the innominate bone are classified into type I (iliac wing) 26 patients, type II (acetabulum) 4 patients & type III (pubic rami) 4 patients.**

Histopathology	No. of cases	Location of tumor		
		Ilium	Acetabulum	Pubic bone
Ewing's sarcoma	14	8	2	4
Chondrosarcoma	12	10	2	
Giant cell tumor	4	4		
Aneurysmal bone cyst	4	4		

Patient	Type of resection	Histology	Complications	Local failure	Distant failure
8	I	Ewing's sarcoma	8 wound sepsis	-	-
4	I,II			-	-
2	III			-	-
10	I	Chondrosarcoma	Two wound sepsis	Two patient 19 months	Two patients disseminated 16 months
2	I,II		One patient prolonged wound drainage	-	-
4	I	Giant cell tumor	One patient prolonged wound drainage	Two patient 12 months	-
4	I	Aneurysmal bone cyst		-	-

<b>Type of Resection</b>	<b>No. of cases</b>
<b>Type I</b>	<b>26 (76.47%)</b>
<b>Type I, II</b>	<b>4 (11.76%)</b>
<b>Type III</b>	<b>4 (11.76%)</b>

# Functional Analysis

All patients were treated in balanced suspension for two weeks post-operatively.

Ambulation was permitted on a partial weight bearing basis with crutches.

In type I & III internal hemipelvectomy, when the hip joint was retained good function was achieved in all 30 patients.

In type II internal hemipelvectomy, as acetabulum was resected, the final result was a flail hip. Rehabilitation took several months. Ambulation without the use of crutches inspite of 7-10 cm leg length discrepancy and limited hip motion was feasible.

## Technique for type I internal hemipelvectomy

The patient was placed semi-prone. The incision was extended from the P.S.I.S to symphysis pubis anteriorly. The abdominal muscles were detached from the iliac crest, peritoneum displaced medially, inguinal ligament was divided near A.S.I.S and the inferior epigastric vessels were divided and ligated. The psoas muscle, iliac vessels and ureter were retracted medially and iliacus muscle was divided at the level of sacroiliac joint. The gluteus maximus was cut inferior and posterior to the greater trochanter.

The sacroiliac joint was exposed and divided with an osteotome. The lesion was removed with the contiguous ilium. The extremity was placed in balanced suspension.

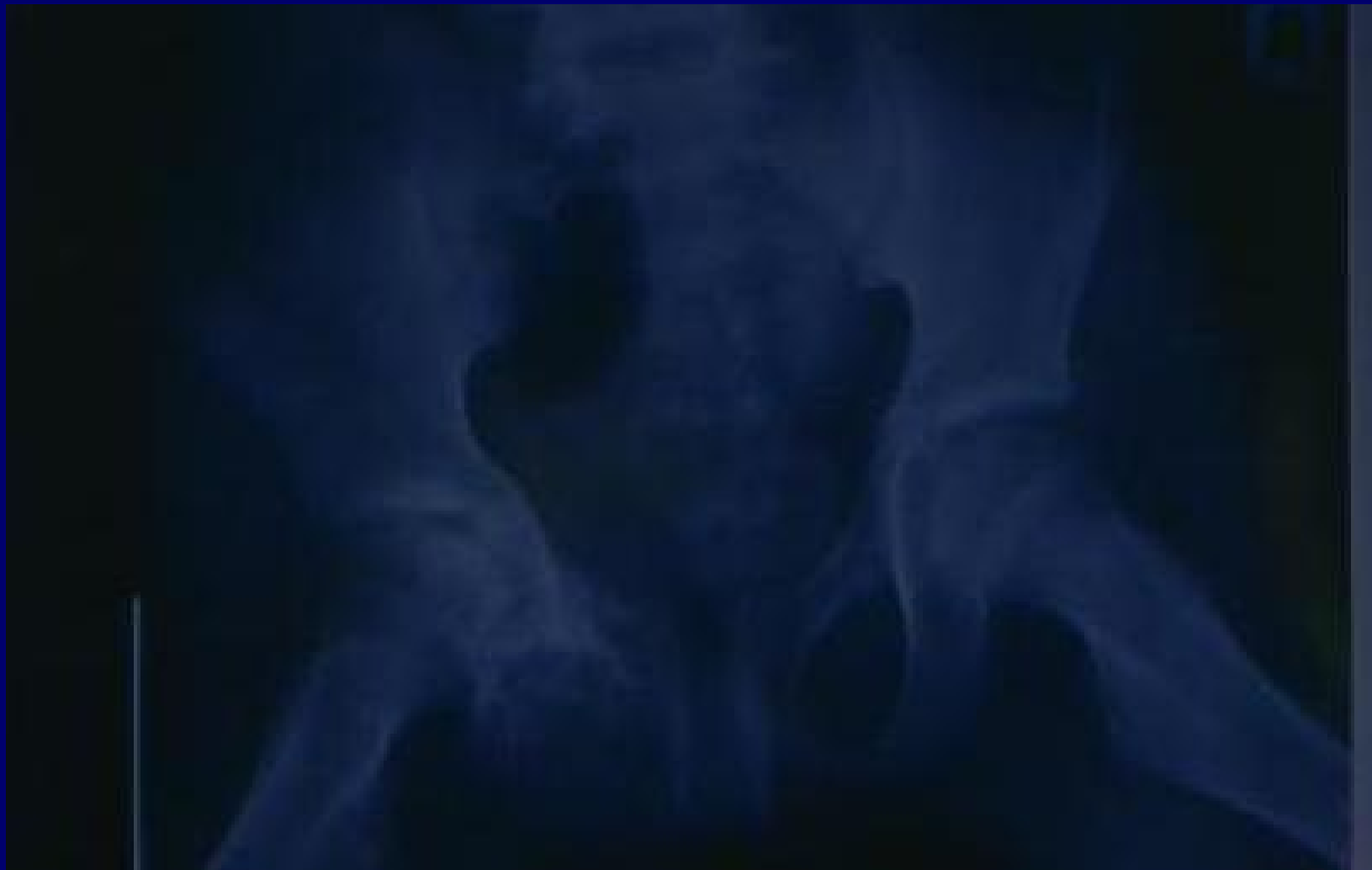A Gigli saw was passed through the greater sciatic notch and the iliac wing was divided.

## **Technique for type II internal hemipelvectomy**

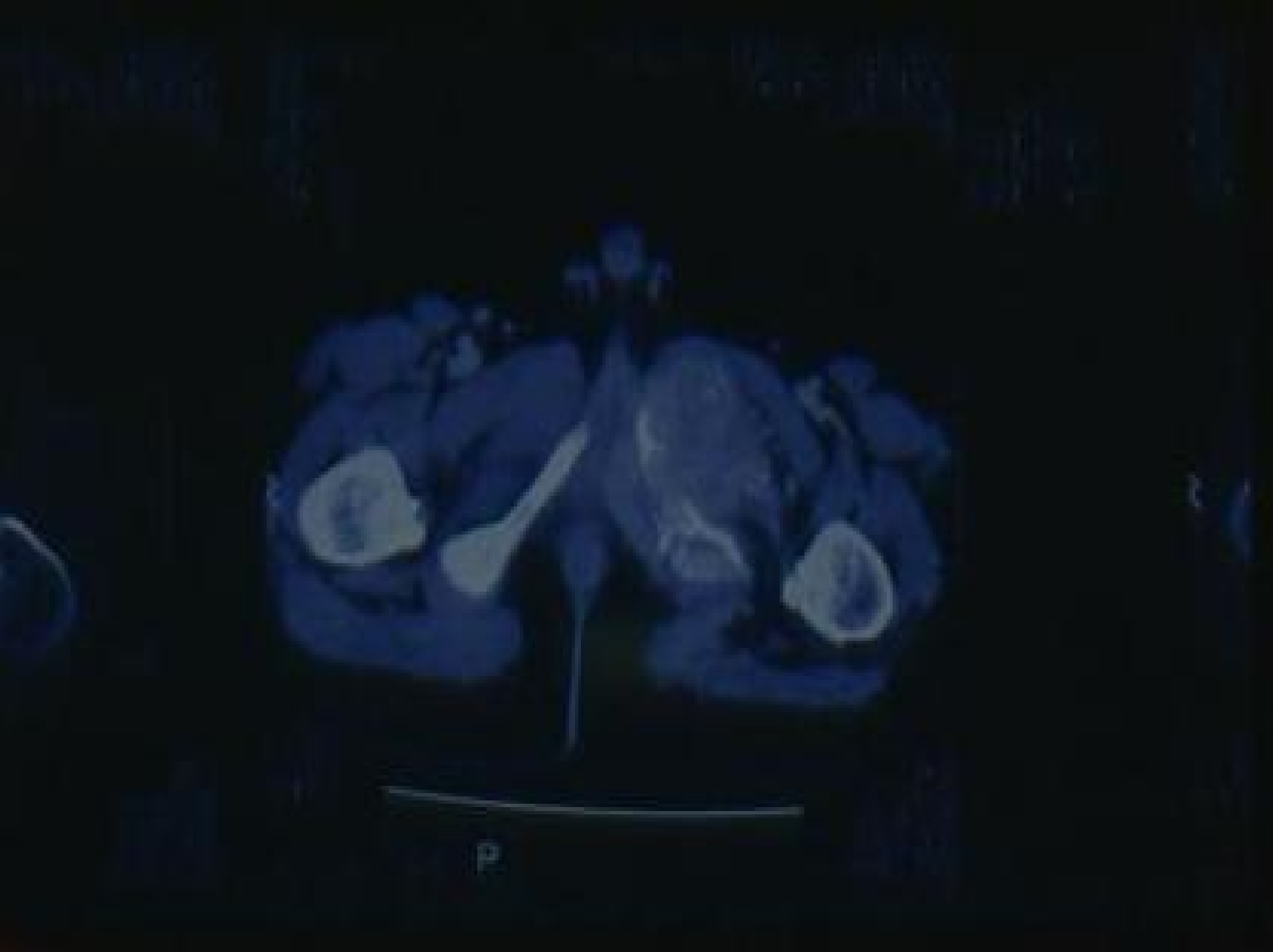
**As in type I, however the pubic bone or symphysis pubis of the divided anteriorly. Then with Kirchner wire the head of the femur was fixed to the remaining part of the innominate bone.**

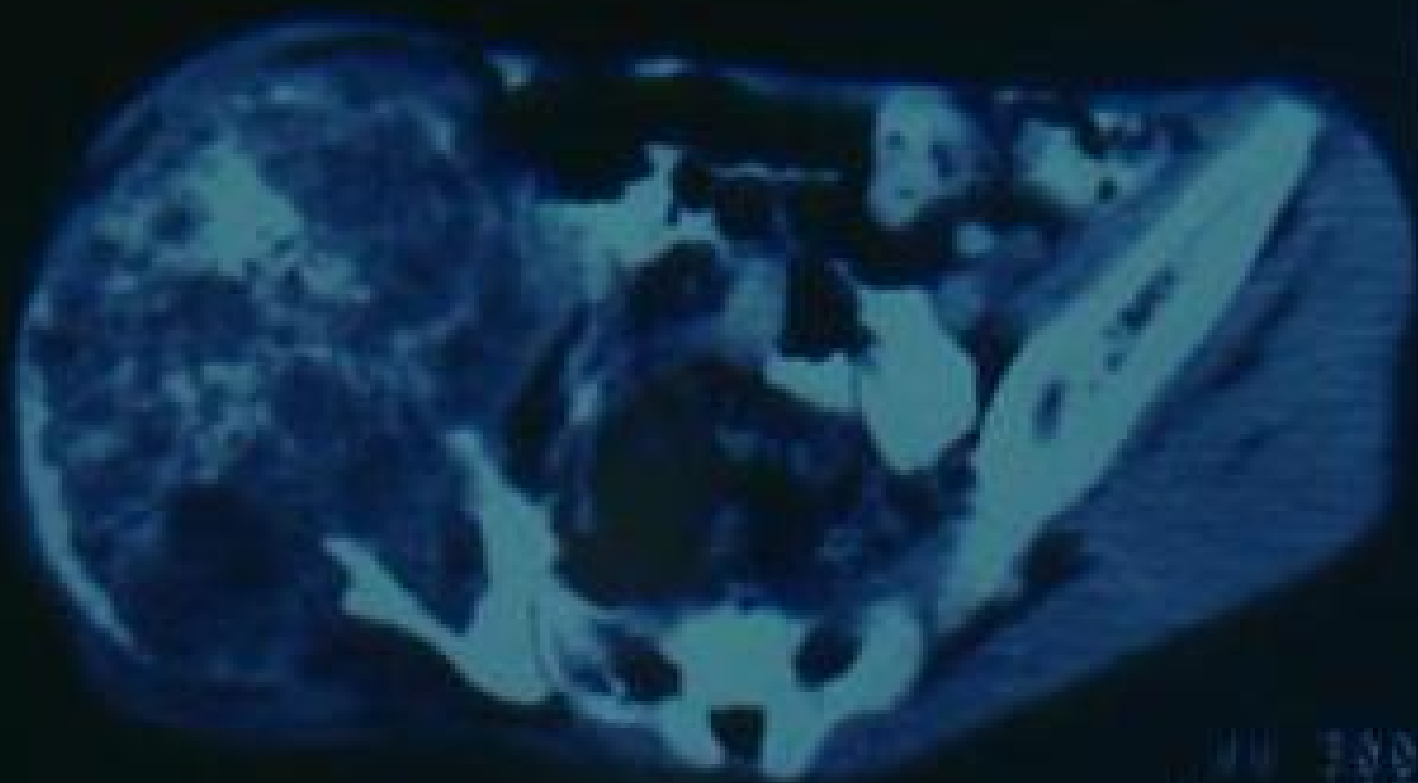
## **Technique for type III internal hemipelvectomy resection of the pubis**

**The patient was placed in lithotomy position. The incision was made 1 cm distal to the middle of poupart's ligament. The adductor and obturator externus muscles were detached from the pubis and ischium, the body of pubis, the lateral surface of inferior ramus of ischium and ischial tuberosity were exposed. The urogenital diaphragm was dissected from the inferior border of the symphysis pubis but avoiding injury of the urethra, deep dorsal vein and dorsal artery and nerve of the penis. The obturator internus muscle was dissected subperiosteally and after that the bone was divided superiorly with bone cutting forceps and inferiorly with Gigli saw.**

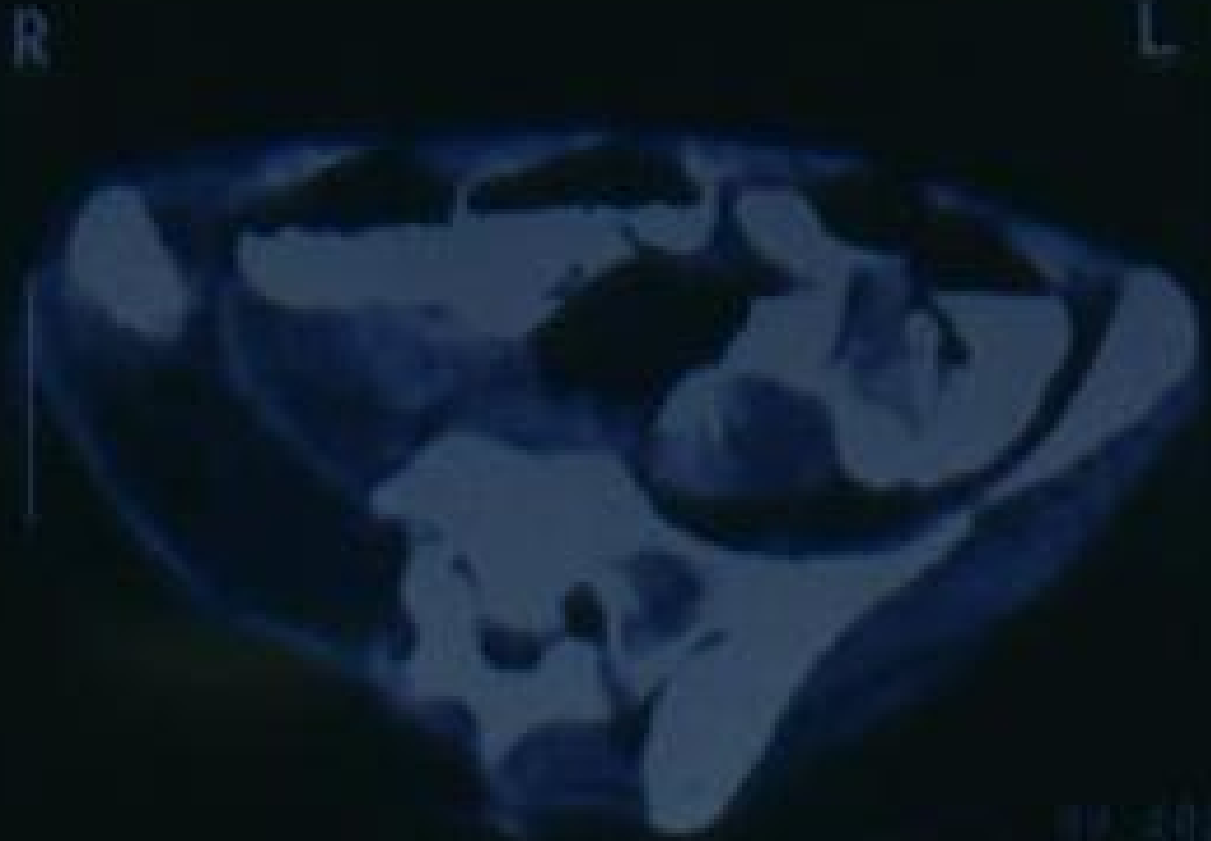

Preoperative X-ray of Rt pubic Ewing sarcoma.

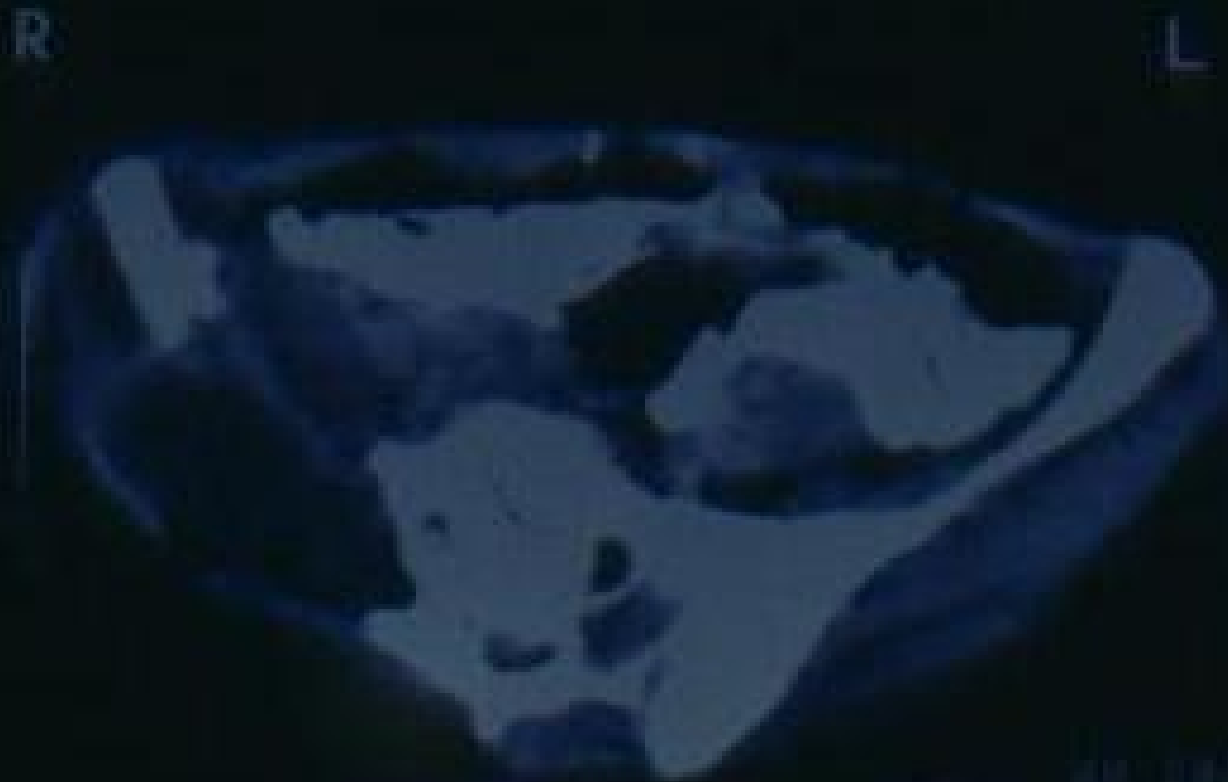



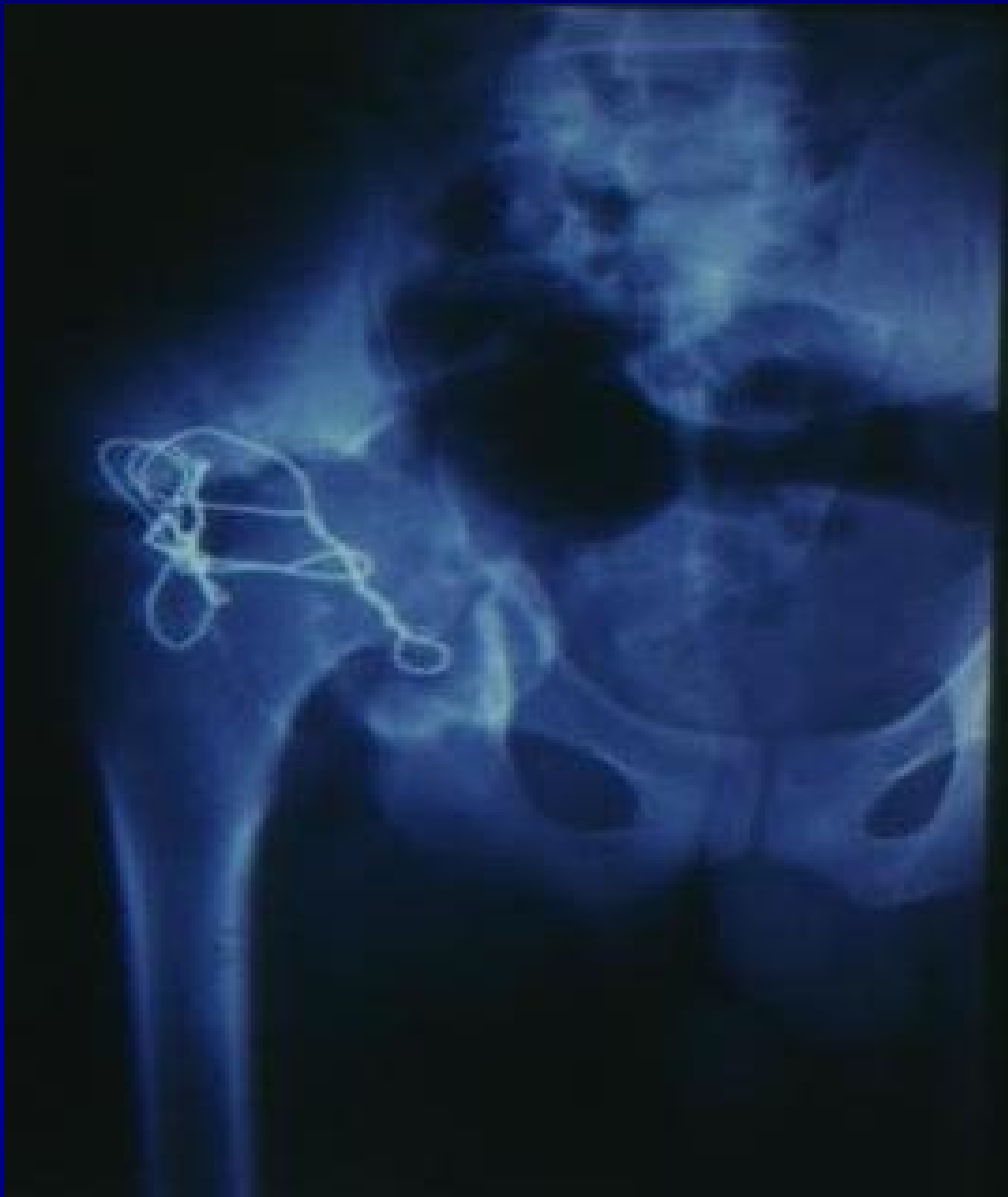Preoperative C.T. for aneurysmal bone cyst.



Postoperative C.T. of pelvis after type II internal hemipelvectomy for aneurysmal bone cyst.



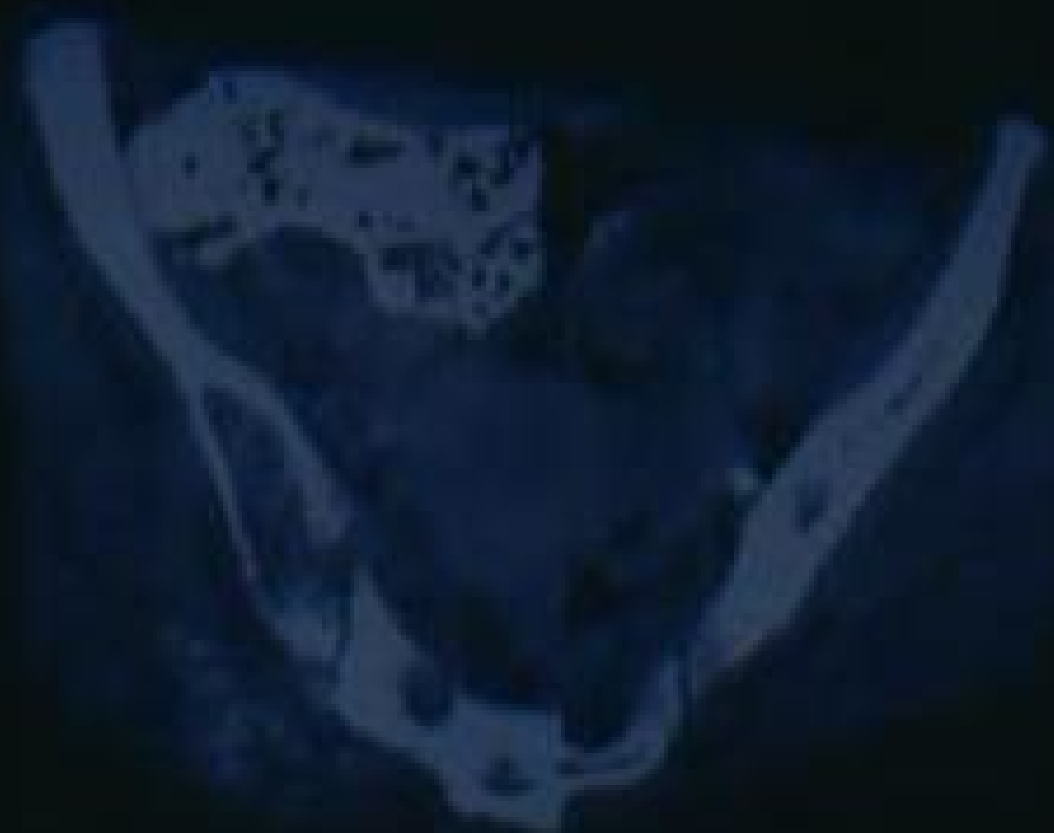Postoperative C.T. of pelvis after type II internal hemipelvectomy for aneurysmal bone cyst.

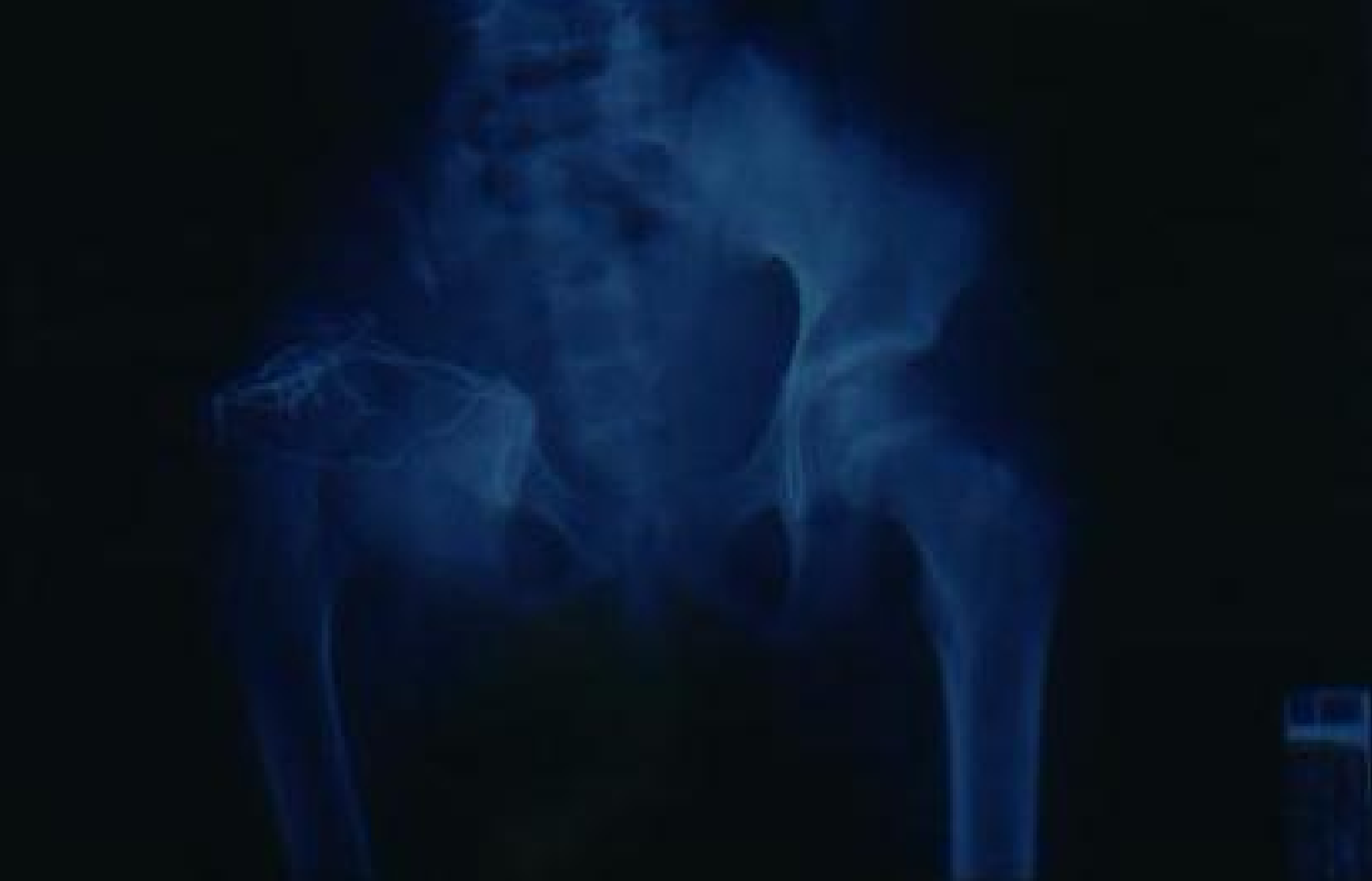

Postoperative X-ray after type I,II internal hemipelvectomy.

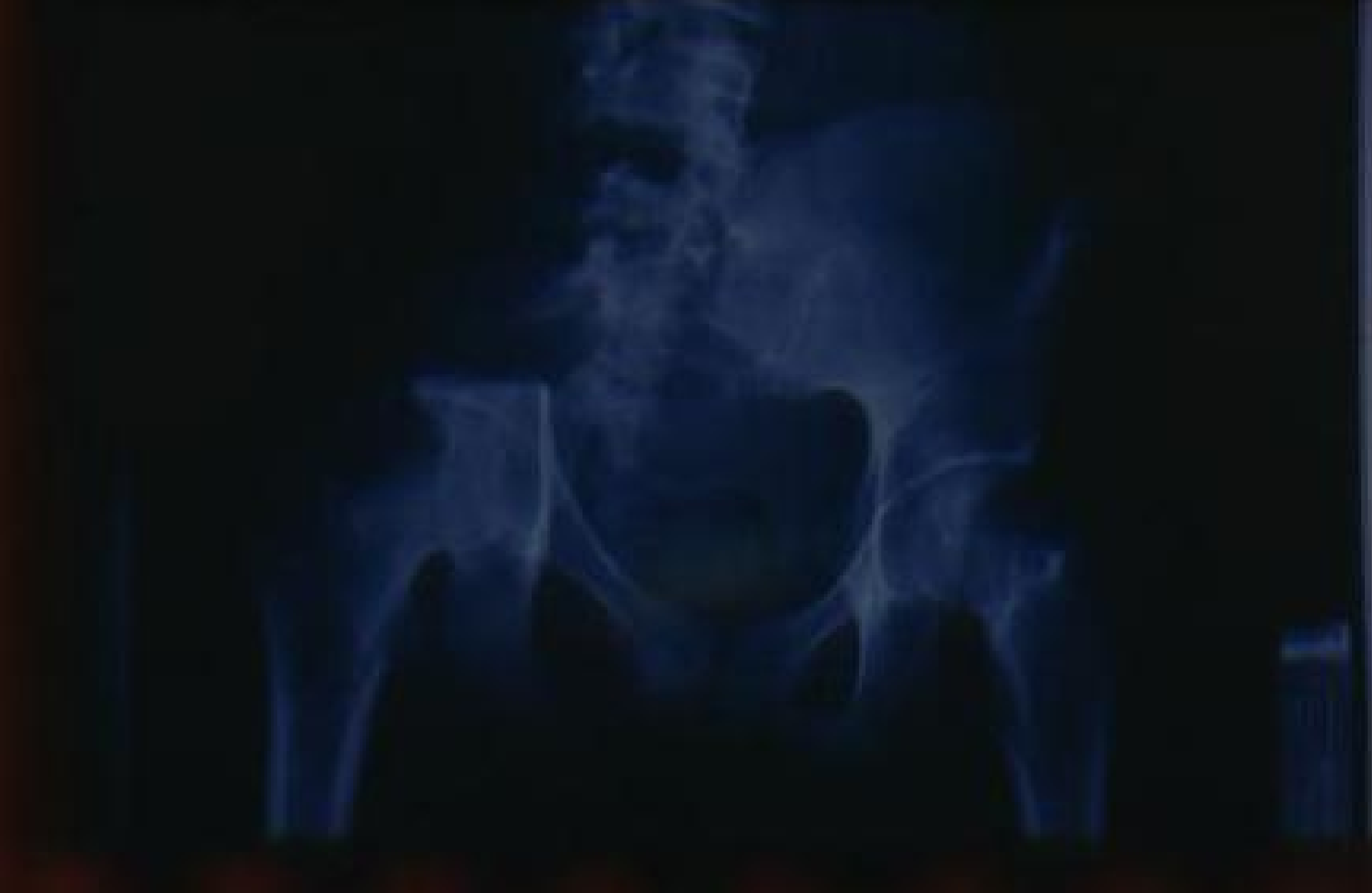1875  
1876  
1877  
1878  
1879  
1880  
1881  
1882  
1883  
1884  
1885  
1886  
1887  
1888  
1889  
1890  
1891  
1892  
1893  
1894  
1895  
1896  
1897  
1898  
1899  
1900

1899





Postoperative X-ray after type I,II internal hemipelvectomy.



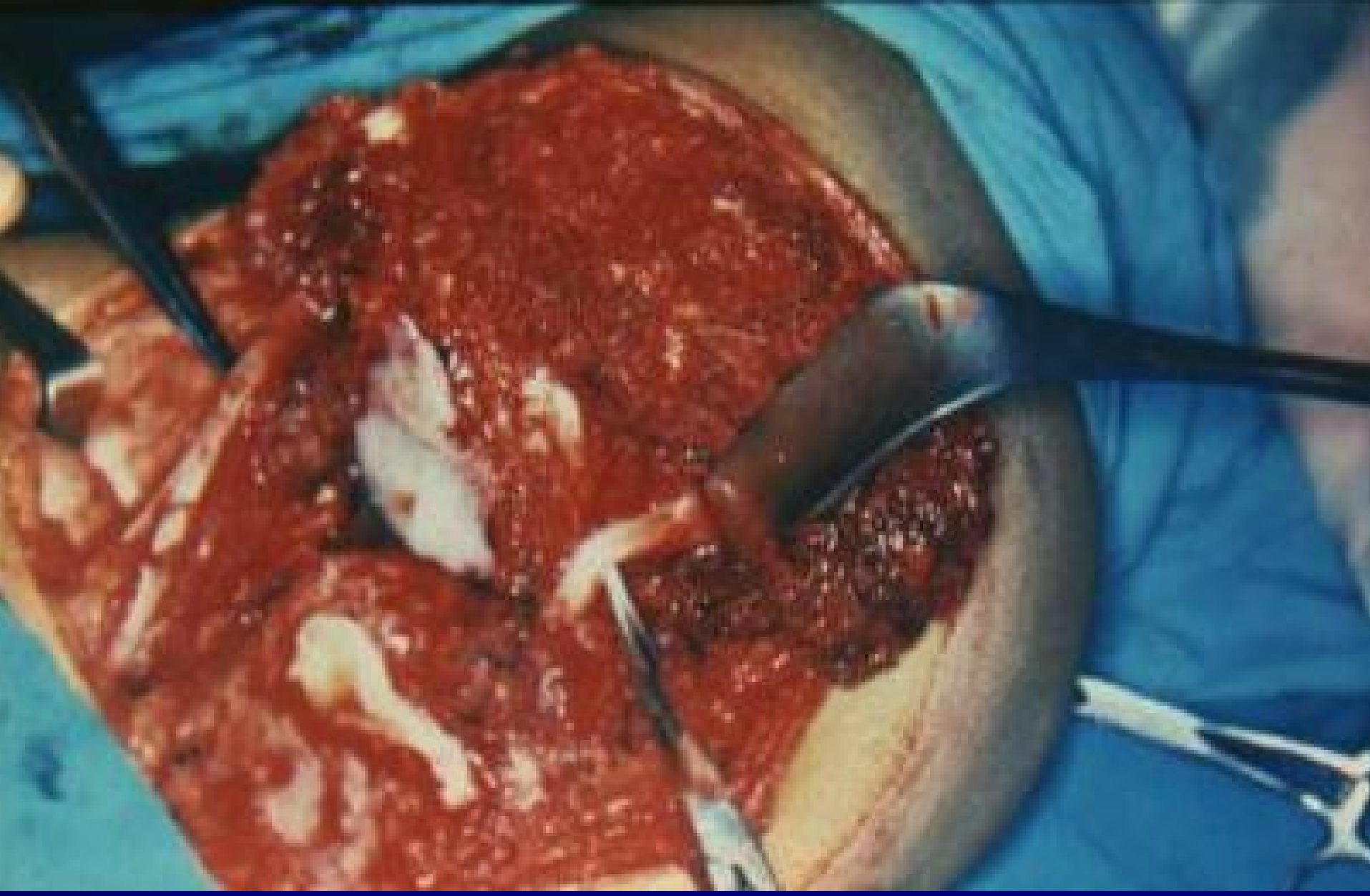
Postoperative X-ray for type I internal hemipelvectomy (iliac wing resection).

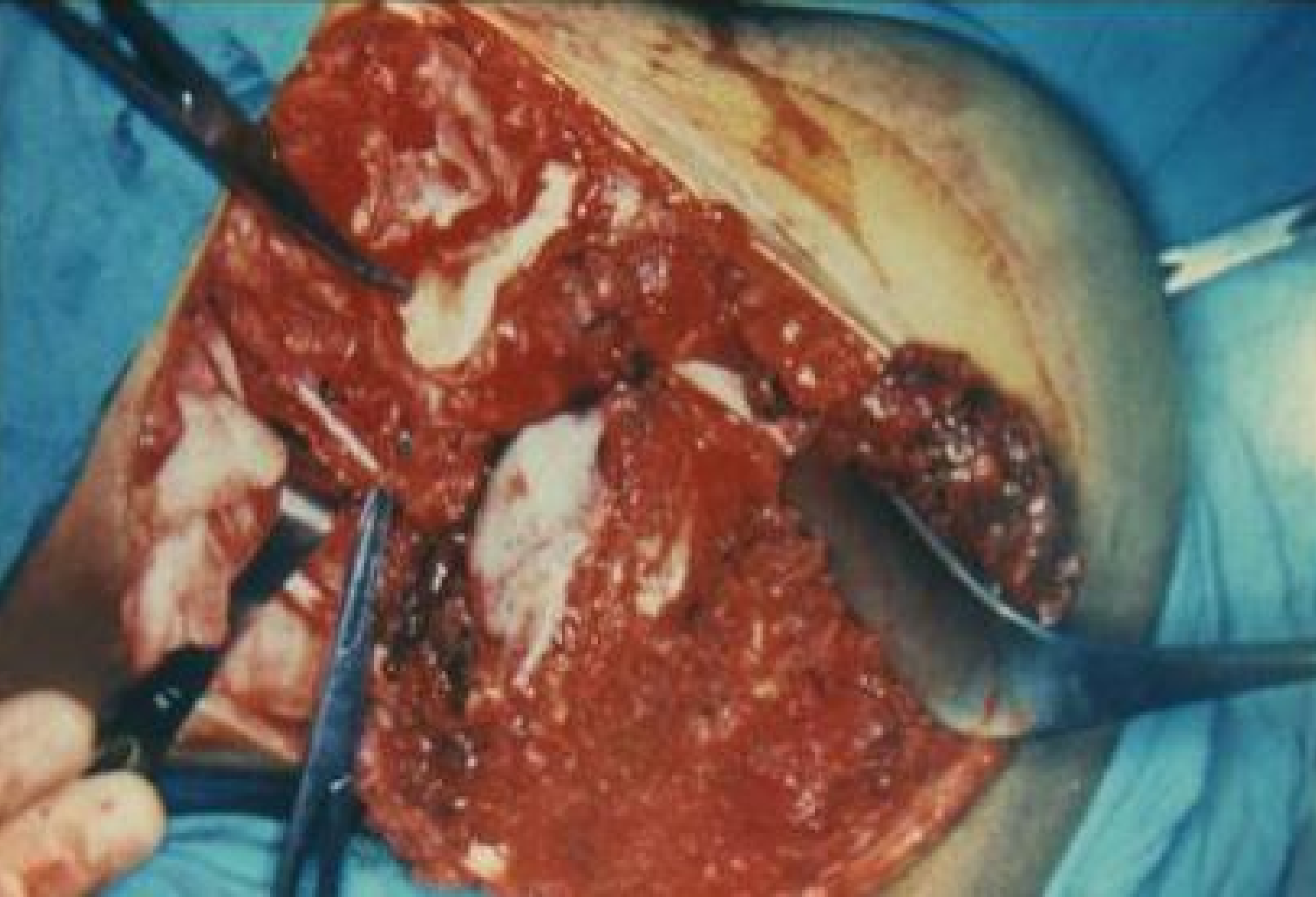
R

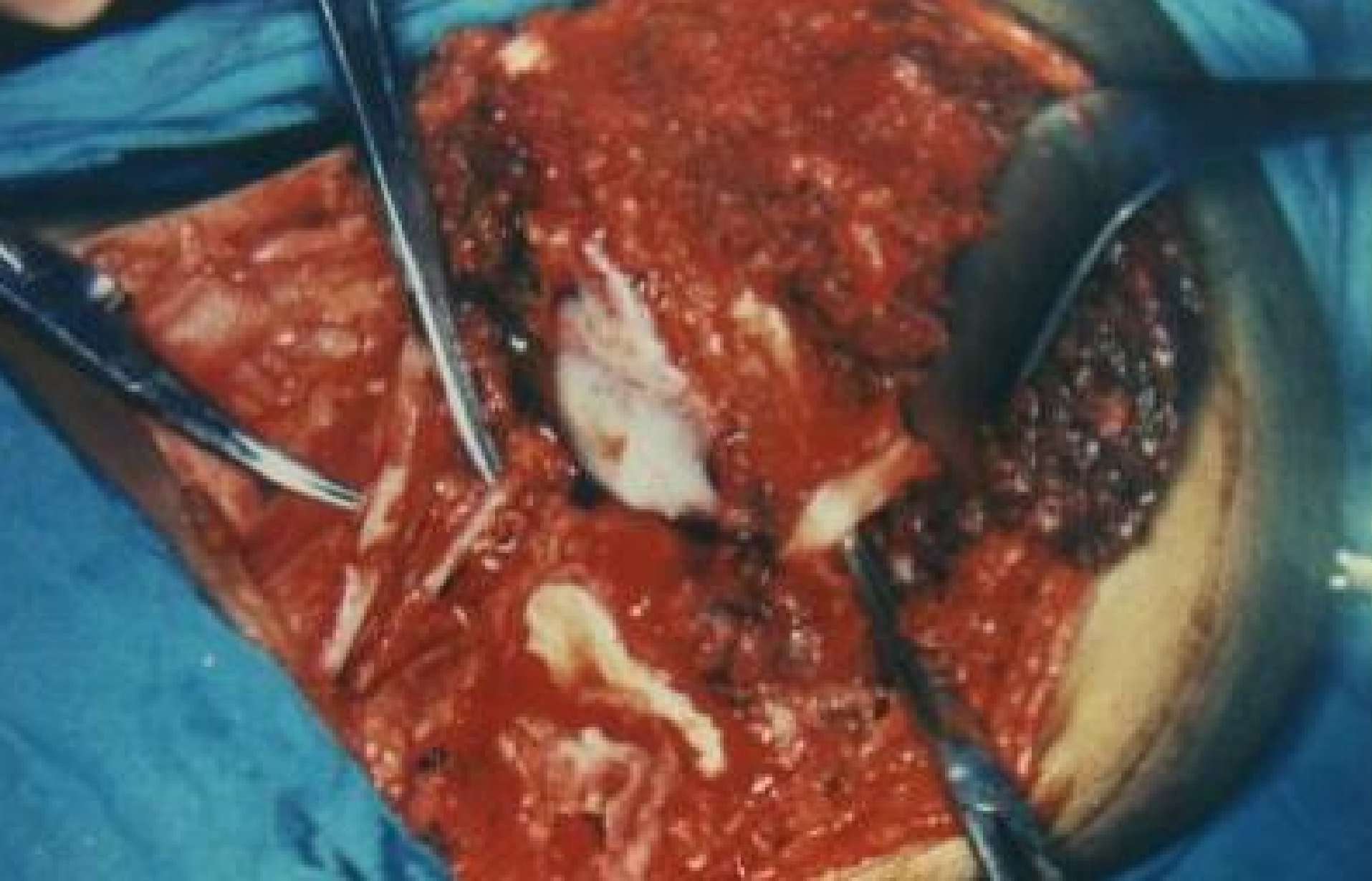L



Postoperative C.T. of pelvis after type II internal hemipelvectomy for aneurysmal bone cyst.







Operative field after type I internal hemipelvectomy.



10 months after internal hemipelvectomy.